

Ramsay Hunt Syndrome with Numerous Cranial Nerve Damage Revealing An HIV Infection: A Case Report

Youssef El Khalifa*, Othman Benhoummad, Aitlhadj Mohamed Amine, Youssef Lakhdar, Youssef Rochdi, and Abdelaziz Raji

ABSTRACT

Ramsay-Hunt syndrome corresponds to a Varicella zoster infection recurrence in the facial nerve's sensory ganglion cells in patients with primary varicella infection. It manifests by coetaneous lesions of the sensitive Ramsay-Hunt zone, peripheral facial paralysis, and audio-vestibular signs. The prognosis is usually good with well-conducted anti-viral treatment. We report the case of a 49-year-old lady who presented with several cranial nerve injuries, including impairment to cranial nerves V, VII, VIII, IX, and X, along with left facial paralysis, vesicles, discomfort in the left ear, dysphagia, and dysphonia. Her work-up in the search for an immune deficiency objected to an HIV infection. This case study aims to raise awareness among doctors to evaluate Ramsay Hunt syndrome in a patient with HIV who presents ear discomfort and insists on a diversified approach to patient care.

Submitted: April 23, 2023

Published: March 04, 2024

 10.24018/ejclinmed.2024.5.2.289

ENT and Cervico-Facial Surgery
Department, University Hospital of
Marrakech, Faculty of Medicine and
Pharmacy, Morocco.

*Corresponding Author:
e-mail: elkhalifayoussef@gmail.com

Keywords: Case report, cranial nerve damage, HIV infection, Ramsay Hunt syndrome.

1. INTRODUCTION

Ramsay Hunt syndrome is a delayed recurrence of varicella zoster infection in the lymph node and it generates sensory and motor neuropathy. At various frequencies, the cranial nerves V, VII, VIII, IX, X, XI, and XII may be affected [1]–[5]. Nevertheless, Ramsay Hunt syndrome has also been linked to the herpes simplex virus type 2 (HSV 2) [6]. Several risk factors have been shown to predispose a person to this illness. The typical trio of ear discomfort, blistering, and ipsilateral facial palsy is utilized to establish a diagnosis. In addition, dysgeusia, hearing loss, tinnitus, hyperacusis, dizziness, tearing, and a change in the quality of the voice have all been noticed [1], [2]. Most treatments are a combination of antivirals and corticosteroids, along with various supplemental modalities such as artificial tears, eye patches, and face exercises [7].

This case focuses on the way the Ramsay Hunt syndrome manifests clinically as numerous cranial nerve involvement may reveal an acquired immune deficiency syndrome.

2. PATIENT AND OBSERVATION

A 47-year-old divorced patient from Guelmim who resides in Marrakech presented to the emergency room with multiple symptoms evolving over 7 days, made up of vesicular lesions in the left pinna and the sensitive area of the trigeminal (Fig. 1).

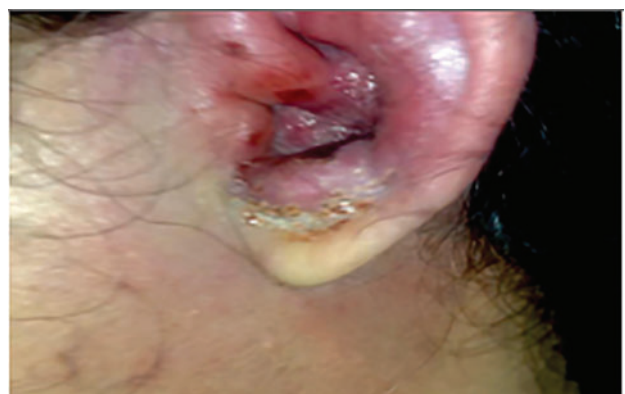

Fig. 1. Dermatological lesion revealing Ramsay-Hunt syndrome.

The patient's condition has worsened after 4 days presenting a peripheral facial paralysis and insomnia otalgia resistant to symptomatic treatments with dysesthesia of the left tongue, headaches, dizziness and dysphonia. Moreover, the patient reports taking non-steroidal anti-inflammatory drugs for 4 days.

Her vital signs were within the ideal range at the time of the initial clinical evaluation in the emergency room. In an agitated patient who was being examined physically, the left pinna was erythematous, edematous, and covered with impetiginous vesicular lesions and pustular lesions, together with left perioral vesiculo-pustular lesions (Fig. 2).

Examination of the oral cavity indicated an edematous that is not contagious as well as a coated vesicular rash, impacting the oropharynx, the entire left side of the oral cavity. The mobility of the palate was affected on the left side (Fig. 3).

Nasofibroscope revealed left palsy of the left vocal cord with vesicular and edematous rashes on the left side of the larynx (Fig. 4).

On neurological examination, complete facial paralysis was apparent, facial function was rated V on the House-Brackman Classification (Fig. 5).

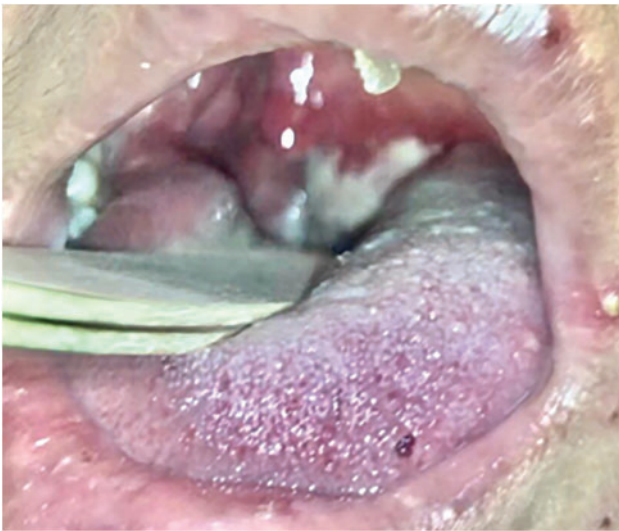

Fig. 2. Vesiculo-pustular perioral lesions.

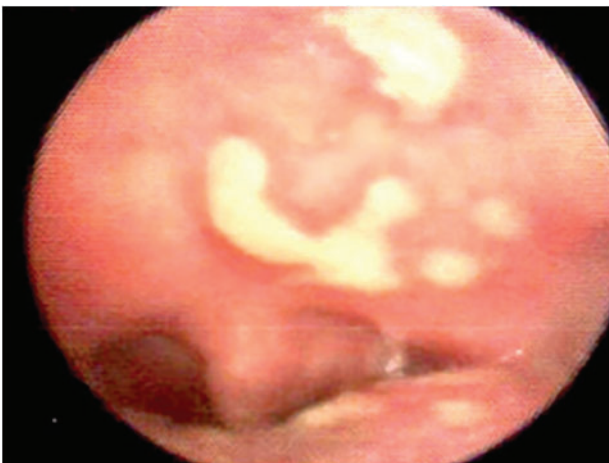


Fig. 3. The mobility of the palate was affected on the left hemiparesis side.

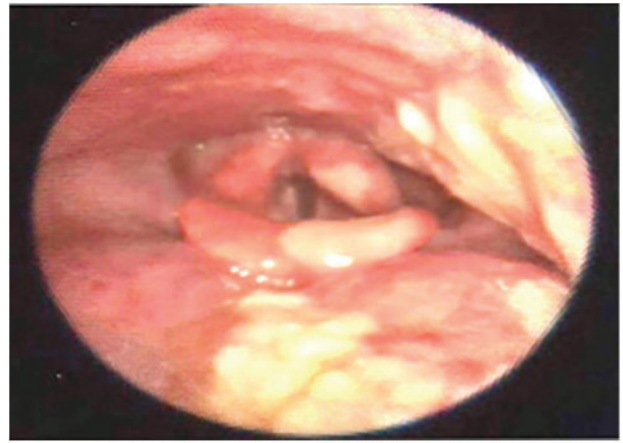


Fig. 4. Edematous rashes in the left hemi-larynx.

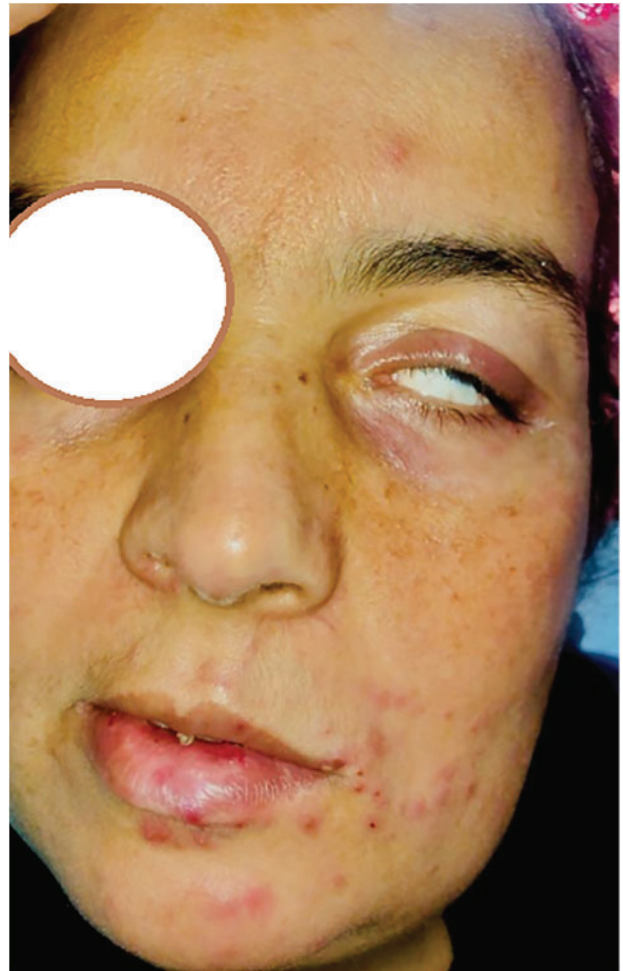

Fig. 5. Facial palsy grade V the House-Brackman classification.

The ophthalmologic examination objectified a left lagophthalmos with a pseudo-dendritic ulcer in the left cornea. Standard blood work was done, revealing a low white cell count. Further investigations were conducted in search of an immune deficiency that objectified a confirmed HIV infection.

The patient was put on IV treatment with aciclovir 10 mg/kg every 8 hours, ciprofloxacin 500 mg twice a day, and C3G 2 g per day for 10 days. There was good improvement in locoregional lesions and overall condition, with regression of facial paralysis to stage III and no recurrent

paralysis. Within a span of a few months under facial and speech therapy, a retroviral treatment was instituted after a complete assessment of the opportunistic infections.

3. DISCUSSION

Ramsay-Hunt syndrome is the term used to describe the typical ear discomfort, vesicles, and facial paralysis brought on by the infection reactivating in the geniculate ganglion.

Several designations, including herpes *zosteroticus* (J. Ramsay Hunt), *zonacephalicus* [8], and *zoster sinus herpes* (without rash [9]–[12]), have been used to characterize this illness because of its diverse clinical manifestations. According to epidemiology, the facial nerve (VII) and the ophthalmic division of the trigeminal nerve (V1) are the most often afflicted cranial nerves (Ramsay Hunt area). According to a recent literature analysis, which only recorded 57 occurrences [13], involvement of additional cranial nerves is uncommon.

Involvement of additional cranial nerves, especially VII and VIII, is typically (83% of cases) linked to glossopharyngeal and vagus herpes zoster [14]. Herpes zoster cephalicus would be the most accurate word to use based on the clinical presentation of our case, as there was damage to cranial nerves IX and X, cranial nerve VII, and cranial nerve V, which affected swallowing and left facial sensibility (dysphagia and dysphonia). When compared to age-matched controls, those with HIV had a 15-fold higher incidence [15].

HIV patients' immunodeficient states make them vulnerable to recurrent infections, disseminated infections, neurological problems, and post-treatment neuralgia [15]. The idea that many cranial nerves are involved takes into account things like anatomical closeness, the nerves' embryological origins, and their hematogenous and transaxonal propagation.

4. CONCLUSION

The Ramsay Hunt remains a quite common syndrome faced in daily practice. However, medical professionals should be wary of an HIV infection in cases of multiple cranial nerve damage associated with it. Furthermore, they should be diligent in searching for opportunistic infections in these patients, always keeping protective measures in mind during examinations.

INFORMED CONSENT

The patient gave consent for the publishing of the pictures and article.

CONFLICT OF INTEREST

Authors declare that they do not have any conflict of interest.

REFERENCES

- [1] Adour KK. Otolological complications of herpes zoster. *Ann Neurol.* 1994;35(Suppl):62–4.
- [2] Mishell JH, Applebaum EL. Ramsay-Hunt syndrome in a patient with HIV infection. *Otolaryngol Head Neck Surg.* 1990;102(2): 177–9.
- [3] Aviel A, Marshak G. Ramsay-Hunt syndrome: a cranial polyneuropathy. *Am J Otolaryngol.* 1982;3:61–6.
- [4] Payton RJ, Dawes JDK. Herpes zoster of the head and neck. *J Laryngol Otol.* 1972;86:1031–55.
- [5] Macsumoto Y, Yanagihara N, Sdamoto M. Gd-DTPA imaging in peripheral facial palsy. *Facial N Res Jpn.* 1991;11:93–6.
- [6] Diaz GA, Rakita RM, Koelle DM. A case of Ramsay Hunt-like syndrome caused by herpes simplex virus type 2. *Clin Infect Dis.* 2005;40(10):1545–7.
- [7] Monsanto RD, Bittencourt AG, Neto NJB, Beilke SCA, Lorenzetti FTM, Salomone R. Treatment and prognosis of facial palsy on Ramsay Hunt syndrome: results based on a review of the literature. *Int Arch Otorhinolaryngol.* 2016;20(4):394–400.
- [8] Blackley B, Friedmann I. Wright Herpes zoster auris associated with facial nerve palsy and auditory nerve symptoms. *Acca Otolaryngol.* 1967;63:533–50.
- [9] Vafai A, Berger M. Zoster in patients infected with HIV: a review. *Am J Med Sci.* 2001;321(6):372–80.
- [10] Gilden DH, Dueland AN, Devlin ME, Mahalingam R, Cohrs R. Varicella-zoster virus reactivation without rash. *J Infect Dis.* 1992;166:30–4.
- [11] Meylan PRA, Miklossy J, Iten A, Petignat C, Meuli R, Zufferey J, et al. Myelitis due to varicella-zoster virus in an immunocompromised patient without a cutaneous rash. *Clin Infect Dis.* 1995;20:206–8.
- [12] Hunt JR. On herpetic inflammation of the geniculate ganglion and its complications. *J Nerv Ment Dis.* 1907;34:73–96.
- [13] Arya D, Bajaj T, Gonzalez J, Elkin R. Ramsay Hunt syndrome with multiple cranial neuropathy in a human immunodeficiency virus (HIV) patient. *Am J Case Rep.* 2018;19:68–71.
- [14] Furuta Y, Takasu T, Fukuda S, Sato-Matsumura KC, Inuyama Y, Hondo R, et al. Detection of varicella-zoster virus DNA in human geniculate ganglia by polymerase chain reaction. *J Infect Dis.* 1992;166(5):1157–9.
- [15] Alciato L, Bonfils P, Rubin F. Unilateral oral, pharyngeal and laryngeal vesicles. *Eur Ann Otorhinolaryngol Head Neck Dis.* 2019 Apr;136(2):141–2. doi: 10.1016/j.anori.2018.11.004. Epub 2018 Dec 13.